

**DATE PRESENTING CLINICAL SIGNS**

10.27.2022 Weight loss of 1lb since 2/2022, on/off vomiting, PU/PD (new), more vocal at night and increased appetite.

PATIENT

Suggs Deuber

Current Medications: Prednisolone 2.5mg EOD to every third day sporadic per owner, Vit B12 0.25mLs once a month, Eating RC HP, random treats here and there, Cerenia 4mg PRN. Will have Gabapentin PO prior to scan.

SPECIES

Feline

Lab Results: Increase in SDMA and creatinine from 2/2022. SDMA 15 (10 in 2/2022), Crea 2.6 (1.5 in 2/2022), BUN 25 (20 in 2/2022). USG 1.022 (1.030 in 2/2022), pH 6.0, protein 1+, WBC 6-10/hpf, RBC >100/hpf, bacteria none seen, casts 2+ fine granular 3-5/hpf. T4 and Free T4 WNL. BP 160 mmHg, FeLV/FIV N/N.

BREED

Ragamuffin

Date of Previous IntraPet Ultrasound: 6/16/21 most recent. See attached.
 Sedation: Not required to complete full diagnostic ultrasound.
 Stat Report: Not requested.
 Imaging Performed By: Andi Parkinson, BS, RDMS.

SEX

Neutered Male

ULTRASONOGRAPHIC EXAMINATION OF THE ABDOMEN**Urinary System****AGE**

2/20/2011

The **urinary bladder** is normal in thickness and the mucosal surface is smooth. The bladder is moderately distended. A small amount of suspended, echogenic debris is observed within the lumen. No masses, inflammatory changes or calculi are observed. The region of the trigone and the visible portion of the proximal urethra are normal.

WEIGHT

11.6lbs

The **left kidney** is normal size (3.86 cm in length); normal shape and architecture with smooth peripheral margins. There is a normal 1:3 cortex to medulla ratio with minimal to mild loss of corticomedullary distinction. There is no evidence of pyelectasia, nephroliths, infarcts or hydronephrosis.

INTERPRETED BY

Andrea Nicastro,
 DMV, Diplomate
 DACVIM (Small
 Animal
 Internal Medicine)

The **right kidney** is normal size (3.90 cm in length); normal shape and architecture with smooth peripheral margins. There is a normal 1:3 cortex to medulla ratio with moderate loss of corticomedullary distinction. A few nonobstructive nephroliths are visualized. Trace pyelectasia is present. There is no evidence of nephroliths, infarcts or hydronephrosis.

HOSPITAL NAME

Frederick Road VH

Adrenal Glands

The **left adrenal gland** is normal size (0.45 cm width). Normal shape and glandular echogenicity. The phrenicoabdominal vein and surrounding vasculature are normal.

REFERRING VET

Dr. Beyer

The region of the **right adrenal gland** is evaluated. No obvious pathology is observed.

Spleen

The **spleen** is normal to slightly prominent in size (0.98 cm in width at the level of the hilus) with normal curvilinear peripheral contours. There is appropriate echogenicity and echotexture. No focal lesions are observed. Splenic vasculature is normal.

INVOICE

11912

Liver

The **liver** is subjectively normal in size with normal contours and structure. There is appropriate echogenicity and echotexture. No overt structural evidence of inflammatory, infiltrative, or regenerative pathology is evident. Vascular and biliary tracts are of normal volume with no evidence of congestion. No pathological hepatic lymphadenopathy observed.

The **gall bladder** lumen is moderately distended. The wall is thin and smooth. Luminal contents are anechoic. The cystic and common bile ducts are normal.

Gastrointestinal

The **stomach and intestine** are free of stasis and exhibit normal peristaltic activity. The gastric lumen is not distended. The gastric wall and pylorus are normal in thickness with a normal layering pattern. The pyloric outflow tract is patent. The small intestinal lumen is not dilated. The small intestinal wall thickness is normal with a normal layering pattern and appropriate mural detail. There is disruption in the normal 1:3 muscularis: mucosal ratio in most segments. Discreet masses are not identified. The colonic wall is normal. There is no evidence of an obstructive pattern.

Pancreas

The left limb of the **pancreas** is visible with normal curvilinear peripheral contours. The parenchyma is slightly hypoechoic relative to surrounding omental fat and homogenous in appearance. The pancreatic duct is visible but not overtly dilated (0.17 cm in diameter). There is no evidence of peripancreatic effusion.

Free Abdomen

The **peritoneal cavity** is normal. There is no evidence of inflammation or effusion. The abdominal **lymph nodes** are normal/not visible.

ULTRASONOGRAPHIC FINDINGS

Primary Findings

- Bowel pattern consistent with inflammatory bowel disease. There is some potential for emerging lymphoma. However, neoplasia is considered unlikely at this time. Changes are similar to the previous sonogram.

Secondary Findings

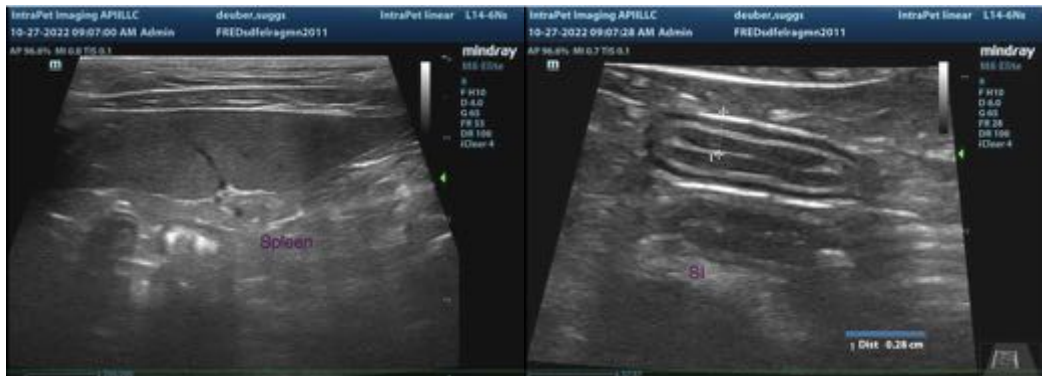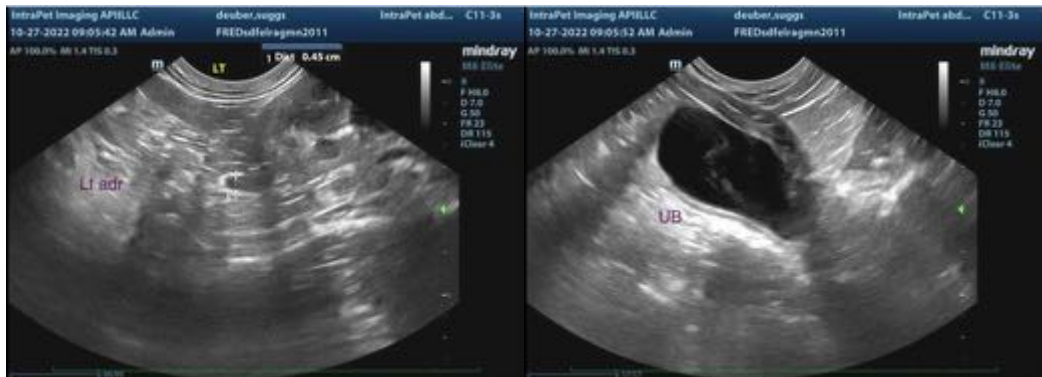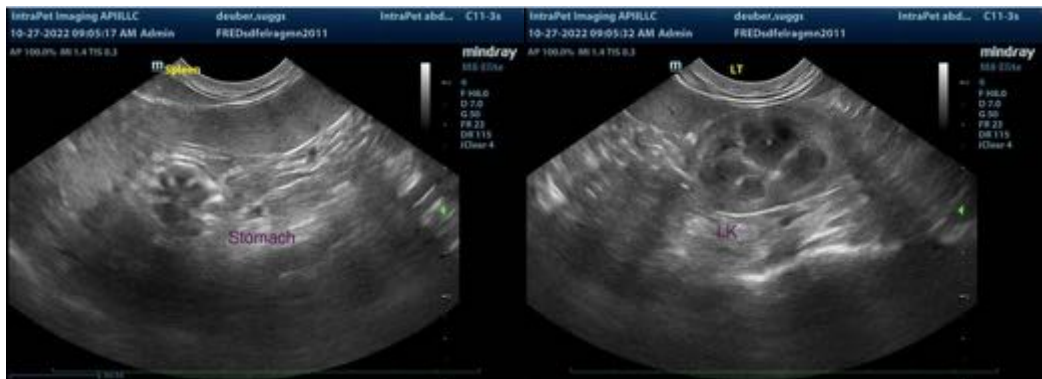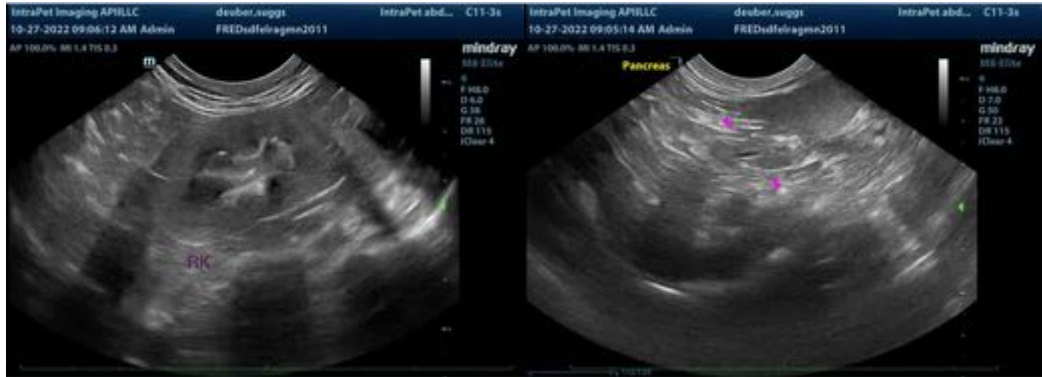
- The pancreas overall appears normal. However, a mild, low-grade, smoldering pancreatitis cannot be completely excluded. Changes are similar to the previous sonogram.
- Bilateral, chronic age-related renal changes with right nonobstructive nephrolithiasis. There is subjective slight progression of pathology compared to the previous sonogram.

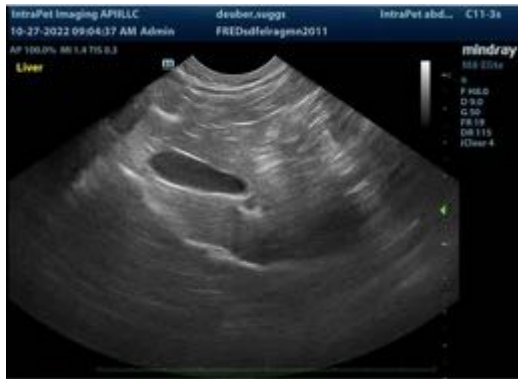INTERPRETATION OF THE FINDINGS & FURTHER RECOMMENDATIONS

Given the recent onset of PU/PD and the presence of pyuria, a urine culture and sensitivity is recommended.

With regard to the weight loss, consider the following:

1. Strict, limited antigen diet or hydrolyzed protein diet
2. Consider acquisition of GI biopsies (endoscopic or surgical) if a definitive diagnosis is desired. Alternatively, empirical treatment for inflammatory bowel disease (i.e., consistent corticosteroid along with the hydrolyzed protein diet) can be considered as long as the client understands the risks of treatment without a definitive diagnosis.





The information and recommendations provided are based on the images presented by the referring veterinarian/sonographer. No evaluation can be communicated regarding pathology that was not visible in the image/video clips provided.

Thank you for this referral. If the clinical or image interpretation does not parallel your findings or if I can be of any further assistance, please contact me.

Andrea Nicastro, MPH, DVM, Diplomate DACVIM (Small Animal Internal Medicine)
info@SonoPath.com